

Virginia Piper Cancer Institute Clinical Service Line
 System-wide Consensus Guidelines: **Ductal Carcinoma In Situ (DCIS): Management of Surgical Margins and Recommendations for Margin Re-excisions in Patients Having Breast Conserving Therapy**

These guidelines apply to clinical interventions that have well-documented outcomes, but whose outcomes may not be desirable for all patients

Reference #: SYS-PC-OCSL-CG-005

Origination Date: June 2011
 Next Review Date: June 2020
 Effective Date: June 2017

Approved Date: June 2017
Approval By: Allina Health Quality Council

System-wide Ownership Group: Allina Health Breast Program Committee
System-wide Information Resource: Director of Clinical Programs

Hospital Division Quality Council Review: May 2017
Allina Health Group Quality Council Review: May 2017

SCOPE:

Sites, Facilities, Business Units	Departments, Divisions, Operational Areas	People applicable to
Allina – All Facilities that perform breast conserving therapy for invasive carcinoma; Abbott Northwestern Hospital, Buffalo Hospital, Cambridge Medical Center, District One Hospital, Mercy Hospital, New Ulm Medical Center, River Falls Area Hospital, Regina Hospital, St. Francis Medical Center, United Hospital	Breast Surgeons Pathology Radiation Oncology Medical Oncology	Physicians, Advanced Practice Providers

Guidelines are not meant to replace clinical judgment or professional standards of care. Clinical judgment must take into consideration all the facts in each individual and particular case, including individual patient circumstances and patient preferences. They serve to inform clinical judgment, not act as a substitute for it. These guidelines were developed by a Review Organization. These guidelines may be disclosed only for the purposes of the Review Organization according to Minn. Statutes §145.64 and are subject to the limitations described at Minn. Statutes §145.65

PICO(TS) FRAMEWORK

Population DCIS patients undergoing breast conserving therapy

Intervention Management of surgical margins

Comparison n/a

Outcomes Ensure adequacy of tumor removal to reduce risk of recurrence

Timing During surgical procedure and subsequent pathologic review

Setting Hospitals where procedure is performed

CLINICAL PRACTICE GUIDELINES:

1. **Wire or seed localization procedures will be utilized intra-operatively in non-palpable lesions, with confirmatory specimen radiographs obtained** to assess adequacy of removal of designated lesion.
2. **The surgeon will orient the lumpectomy margins** using the standard inking scheme (see below). **The surgeon will orient the mastectomy specimen** with a stitch at 12 o'clock.
3. **Specimens will be sent immediately to pathology for evaluation** of margins (for known cancers) and for handling of specimens according ASCO/CAP guidelines.
 - a. If a pathologist is not available on site at the time of surgery, the surgeon is responsible for handling the specimen according to ASCO/CAP guidelines (see attached flow charts for mastectomies and lumpectomies).
4. **Pathologist will grossly assess margin status of known cancers.** Frozen sections may be obtained at pathologist's discretion. Pathologists will report to surgeons any close margins requiring immediate re-excision.
 - a. Pathologist will record time specimen placed in formalin on requisition slip.
5. For DCIS cases that will be treated with whole-breast radiation therapy (WBRT), **all margins involved with DCIS and all DCIS margins at less than 0.2 cm should be considered for re-excision when possible.** The grade of the DCIS, age of the patient, and the volume of DCIS at or near the margin may also influence the decision for re-excision.
6. **DCIS with microinvasion** (defined as no invasive focus greater than 0.1 cm in size) should be considered as DCIS when considering the optimal margin width.
7. **For invasive cancers (greater than 0.1 cm) with a DCIS component,** the adequacy for margin assessment should follow the invasive cancer guidelines (no tumor on ink) since these patients are typically treated with systemic therapy.

Guidelines are not meant to replace clinical judgment or professional standards of care. Clinical judgment must take into consideration all the facts in each individual and particular case, including individual patient circumstances and patient preferences. They serve to inform clinical judgment, not act as a substitute for it. These guidelines were developed by a Review Organization. These guidelines may be disclosed only for the purposes of the Review Organization according to Minn. Statutes §145.64 and are subject to the limitations described at Minn. Statutes §145.65

8. **For patients with invasive tumor and extensive intraductal component (EIC)**, there should be further consideration for determining margin adequacy. Since EIC may be a marker for a potential heavy burden of residual DCIS, post-excision mammography to evaluate for residual targeted calcifications, the presence of multiple close margins, and young patient age can be used to select patients who may benefit from re-excision.
9. **Exceptions should be discussed by the surgeon, radiation oncologist and pathologist, and perhaps presented at a multi-disciplinary conference** (if there are still questions regarding the need for re-excision).

SUPPORTING EVIDENCE:

Margin status is an important issue in the management of patients undergoing breast conserving therapy (BCT) for treatment of invasive carcinoma and ductal carcinoma in situ (DCIS). Most patients are also treated with whole-breast radiation therapy (WBRT). The incidence of ipsilateral breast tumor recurrence (IBTR) in patients with breast cancer who undergo lumpectomy or partial mastectomy has been shown to be directly affected by margin status.

Re-excision of margins for both invasive breast cancer and DCIS in clinical practice is determined by the closeness of the surgical resection margin. Controversy surrounds the recommendations for re-excision for both invasive carcinoma and DCIS since multiple factors including pathologic handling of specimens, tumor characteristics and biology can have an effect on local recurrence.

Intra-operative and pathologic examination of breast specimens has been standardized for Allina Health that are served by Hospital Pathology Associates (HPA). These include orientation of lumpectomy specimens intra-operatively by using a standardized multi-colored inking scheme (blue=superior, red=inferior, green=medial, yellow=lateral, orange=anterior, black=deep). All mastectomy specimens should be oriented with a stitch at 12 o'clock.

A standardized protocol developed by HPA for sectioning the lumpectomy and mastectomy specimens for gross assessment of margins is utilized on all specimens. Specimens are cut at approximately 0.5 cm sections along the long axis of the specimen. Shaved tangential margins are not used since this overestimates the "positive margin rate" and increases the likelihood of unnecessary re-excisions. Intra-operative touch preps are also not advocated for margin assessment because of inconsistent results. The pathologist evaluates the closeness of the margins on gross examination (and when necessary by frozen section). The decision for immediate re-excision is made by joint decision of the pathologist and surgeon. Final margin status for both invasive and non-invasive breast cancer is reported in pathology report for all 6 margins less than 1 cm from tumor.

Guidelines are not meant to replace clinical judgment or professional standards of care. Clinical judgment must take into consideration all the facts in each individual and particular case, including individual patient circumstances and patient preferences. They serve to inform clinical judgment, not act as a substitute for it. These guidelines were developed by a Review Organization. These guidelines may be disclosed only for the purposes of the Review Organization according to Minn. Statutes §145.64 and are subject to the limitations described at Minn. Statutes §145.65

Following gross evaluation, the specimens are placed in 10% neutral buffered formalin within 60 minutes from removal from the patient, and are fixed in formalin for a minimum of 6 hours, not to exceed 72 hours, according to American Society of Clinical Oncology (ASCO) and College of American Pathology (CAP) guidelines.

Scientific information regarding margin status and recurrence for DCIS include a recent Consensus Guideline on Margins for Breast-Conserving Surgery with Whole-Breast Irradiation in Ductal Carcinoma In Situ (1).

1. A positive margin, defined as ink on DCIS, is associated with a significant increase in IBTR. This increased risk is not nullified by the use of WBRT.
2. DCIS margins of at least 2 mm are associated with a reduced risk of IBTR relative to narrower negative margin widths in patients receiving WBRT. The routine practice of obtaining negative margin widths wider than 2 mm is not supported by the evidence.
3. Treatment with excision alone, regardless of margin width, is associated with substantially higher rates of IBTR than treatment with excision and WBRT, even in predefined low-risk patients. The optimal margin width for treatment with excision alone is unknown, but should be at least 2 mm. Some evidence suggests lower rates of IBTR with margin widths wider than 2 mm but that rate has not reached statistical significance.
4. Rates of IBTR are reduced with endocrine therapy, but there is a lack of studies examining the association between endocrine therapy and negative margin width.
5. Multiple factors have been shown to be associated with the risk of IBTR in patients treated with and without WBRT, but there are no data addressing whether margin widths should be influenced by these factors.
6. Choice of WBRT delivery technique, fractionation, and boost dose should not be dependent upon negative margin width. There is insufficient evidence to address optimal margin widths for accelerated partial breast irradiation (APBI).

Additional supporting evidence:

In a review of 4,660 patients treated with BCT and radiation therapy (RT) for DCIS, a negative margin significantly reduced the incidence of IBTR. When margin thresholds were examined, a 2 mm margin was superior to a <2mm margin. However margins >2 mm did not show a decrease IBTR. (2, 5, 12, 25, 28-34)

The volume of tumor near the margin is also important in regards to IBTR. One duct involved within a 2 mm margin is less likely to recur than multiple ducts near or at a margin. And, forty percent of patients with DCIS will have skip lesions, making it common to have residual DCIS in the breast following “clear margins”. (6)

Other biological factors may also affect the risk of IBTR irrespective of the tumor margins. Size and grade of DCIS, presence of necrosis, as well as patient age, have all been shown to increase risk of local recurrence irrespective of the margin status. (2, 12, 25)

Many studies have shown that BCT without radiation therapy is associated with a marked increase in IBTR. Thus, radiation therapy has been proven to be necessary to control residual DCIS in the breast of patients undergoing BCT. (23)

Adjuvant hormonal therapy reduces the risk of local recurrence even further in patients with estrogen receptor positive DCIS. (2, 22-24)

Silverstein's studies with the Van Nuys nomogram have shown that for small low grade DCIS, excision with a 1 cm margin may not require RT with no increase in local recurrence. (25) However, subsequent studies have been unable to duplicate his results. All randomized studies have shown an increase in IBTR for all grades of DCIS in which RT is eliminated. (26)

Invasive cancer with extensive DCIS also referred to as extensive intraductal component (EIC) has a higher rate of local recurrence than invasive cancer without EIC and the recurrences may manifest as DCIS or invasive cancer. Thus, the margin status of DCIS in patients with invasive carcinoma associated with EIC is extremely important in predicting IBTR. (12, 27, 35)

DEFINITIONS: N/A

SPECIAL ENTITIES:

Lobular carcinoma in situ

Lobular carcinoma in situ (LCIS) is a pathological finding associated with an increased risk of developing breast cancer in either breast. However, classic LCIS at or near a margin does not increase the risk of local recurrence, and thus classic LCIS does not require re-excision for margin involvement or proximity. The exceptions to this are special types of LCIS, such as pleomorphic LCIS, and LCIS with necrosis. These "high grade" types of LCIS are thought to behave similarly to DCIS. Thus, re-excision of margins is recommended for pleomorphic type LCIS or LCIS with necrosis located near or at surgical margins (following the guidelines above for DCIS). (36, 37)

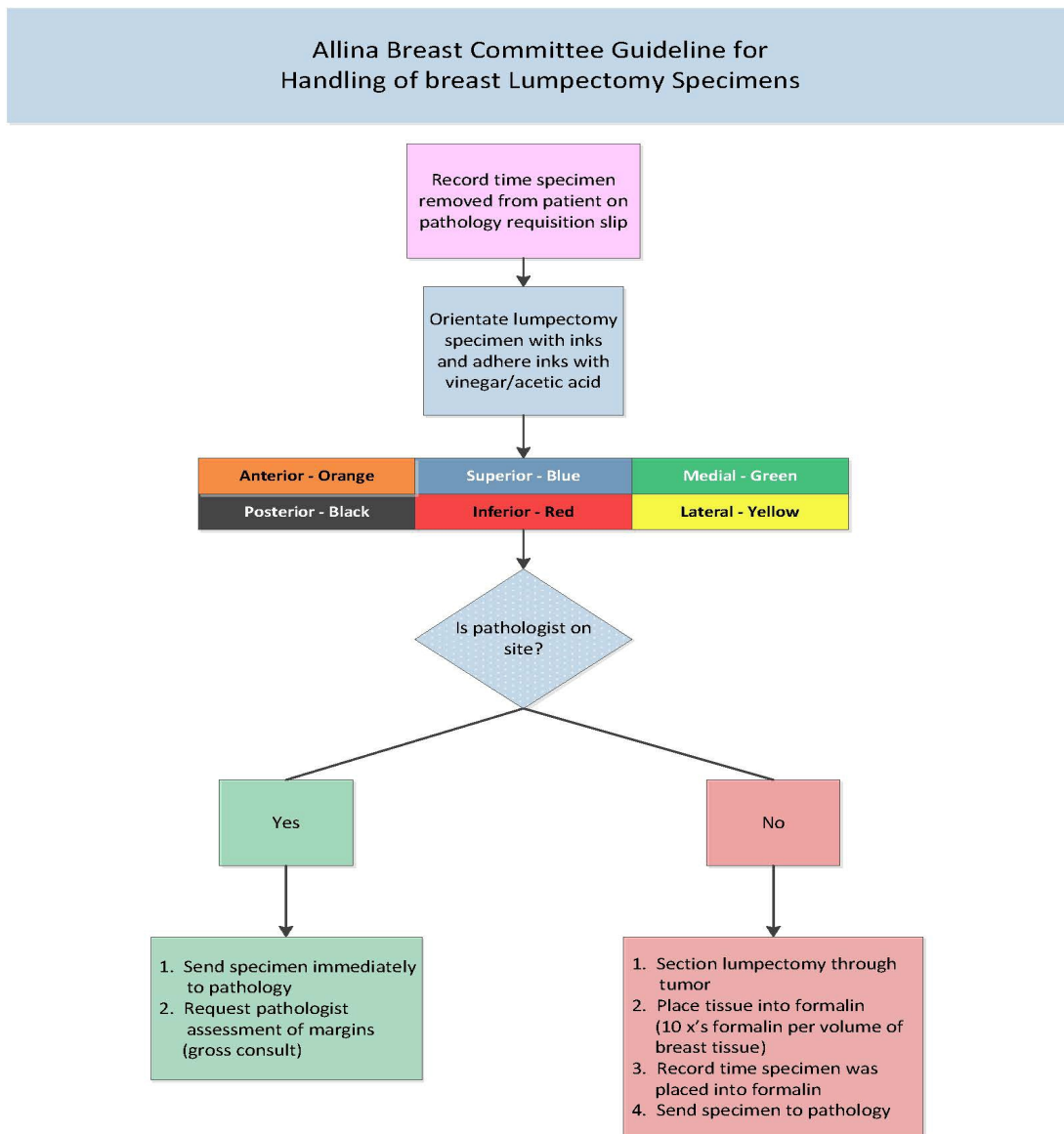
Atypical ductal hyperplasia

Atypical ductal hyperplasia (ADH) has been found to be associated with an increased risk of cancer in the breast. And, in some cases, the classification of ADH may be based on a quantitative assessment of atypical ducts. There may be quantitatively insufficient atypical ducts in a particular specimen to qualify for a diagnosis of DCIS. Thus, if ADH is present at an excised margin in an excisional biopsy specimen, or at an excised margin in a BCT specimen, re-excision will be recommended to exclude the possibility of DCIS at that margin. (38)

FORMS: N/A

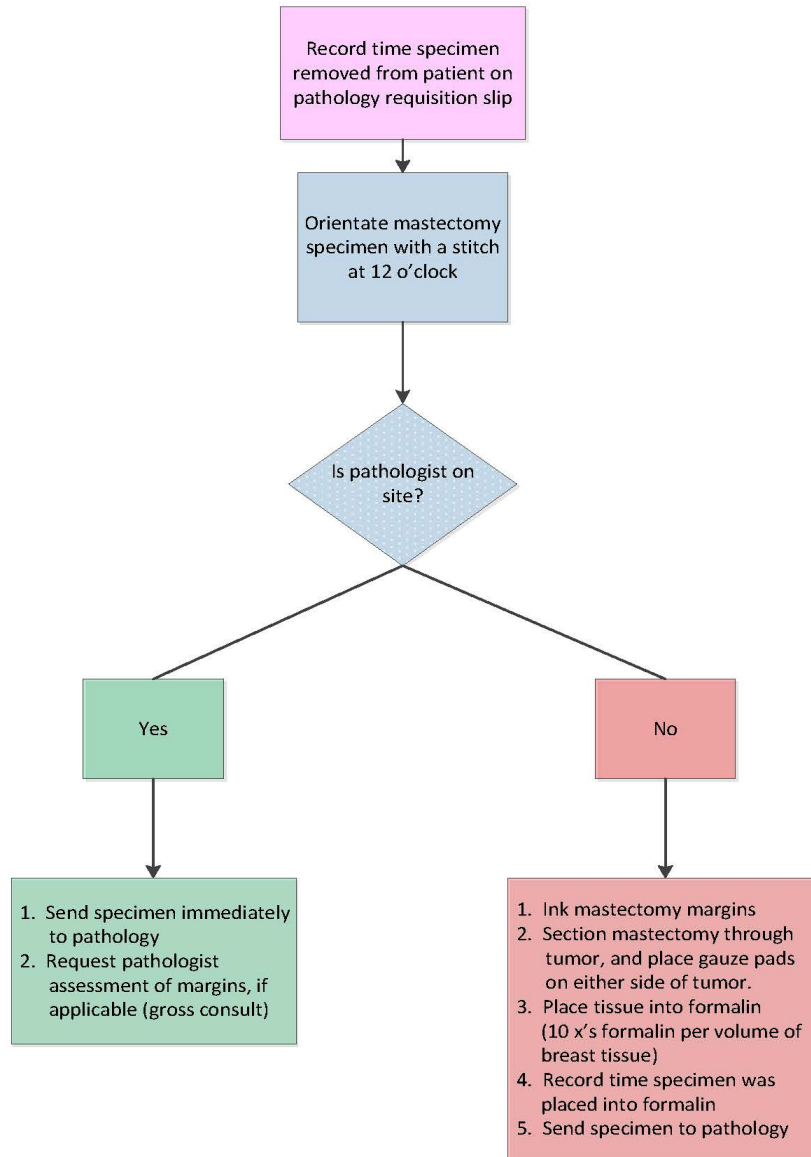
Guidelines are not meant to replace clinical judgment or professional standards of care. Clinical judgment must take into consideration all the facts in each individual and particular case, including individual patient circumstances and patient preferences. They serve to inform clinical judgment, not act as a substitute for it. These guidelines were developed by a Review Organization. These guidelines may be disclosed only for the purposes of the Review Organization according to Minn. Statutes §145.64 and are subject to the limitations described at Minn. Statutes §145.65

ALGORITHM:



Guidelines are not meant to replace clinical judgment or professional standards of care. Clinical judgment must take into consideration all the facts in each individual and particular case, including individual patient circumstances and patient preferences. They serve to inform clinical judgment, not act as a substitute for it. These guidelines were developed by a Review Organization. These guidelines may be disclosed only for the purposes of the Review Organization according to Minn. Statutes §145.64 and are subject to the limitations described at Minn. Statutes §145.65

Allina Breast Committee Guideline for Handling of Breast Mastectomy Specimens



Guidelines are not meant to replace clinical judgment or professional standards of care. Clinical judgment must take into consideration all the facts in each individual and particular case, including individual patient circumstances and patient preferences. They serve to inform clinical judgment, not act as a substitute for it. These guidelines were developed by a Review Organization. These guidelines may be disclosed only for the purposes of the Review Organization according to Minn. Statutes §145.64 and are subject to the limitations described at Minn. Statutes §145.65

ADDENDUM:

Plan for Monitoring and Adherence

Who will be measured for guideline adherence?

- Breast Surgeons

What will be measured? Just in time monitoring will be performed to make certain appropriate handling of specimens is followed. Outliers will be addressed. And, re-excision rates will ultimately be gathered for surgeons.

Where is the data located? The data will be obtained from pathology reports, and additional information may be obtained from the surgeon's operative note.

How will the guideline adherence be monitored?

- It will be monitored through the Breast Program Committee

When will adherence data be collected? TBD – need the dashboard to be built.....

REFERENCES:

1. Morrow M et al: Consensus Guideline on Margins for Breast-Conserving Surgery With Whole-Breast Irradiation in Ductal Carcinoma In Situ *J Clin Oncol* 2016
<http://ascopubs.org/doi/full/10.1200/JCO.2016.68.3573>
2. Morrow M. Breast conservation and negative margins: how much is enough? *Breast* 2009;18(S3):S84-6.
3. Singletary SE. Surgical margins in patients with early-stage breast cancer treated with breast conservation therapy. *Am J Surg* 2002;184:383-93.
4. Kumar S, Sacchini V. The surgical management of ductal carcinoma in situ. *Breast J* 2010;16(suppl 1):S49-S52.
5. Virnig BA, Tuttle TM, Shamliyan T, Kane RL. Ductal carcinoma in situ of the breast: a systematic review of incidence, treatment, and outcomes. *J Natl Cancer Inst* 2010;102:170-8.
6. Rudloff U, Brogi E, Reinger AS, Goldberg JI, Brockway JP, Wynveen CA, et al. The influence of margin width and volume of disease near margin on benefit of radiation therapy for women with DCIS treated with breast-conserving therapy. *Ann Surg* 2010;251(4):583-91.
7. Sanchez C, Brem RF, McSwain AP, Rapelyea JA, Torrente J, Teal CB. Factors associated with re-excision in patients with early-stage breast cancer treated with breast conservation therapy. *Am Surgeon* 2010;76:331-4.
8. Morrow M. Trends in the surgical treatment of breast cancer. *Breast J* 2010;16(suppl 1):S17-9.
9. Rudloff U, Jacks LM, Goldberg JI, Wynveen CA, Brogi E, Patil S, et al. Nomogram for predicting the risk of local recurrence after breast-conserving surgery for ductal carcinoma in situ. *J Clin Oncol* 2010;28(3):3762-9.
10. Millar EKA, Graham PH, O'Toole SA, McNeil CM, Browne L, Morey AL, et al. Prediction of local recurrence, distant metastases, and death after breast-conserving therapy in early-stage invasive breast cancer using a five-biomarker panel. *J Clin Oncol* 2009;27(28):4701-8.

Guidelines are not meant to replace clinical judgment or professional standards of care. Clinical judgment must take into consideration all the facts in each individual and particular case, including individual patient circumstances and patient preferences. They serve to inform clinical judgment, not act as a substitute for it. These guidelines were developed by a Review Organization. These guidelines may be disclosed only for the purposes of the Review Organization according to Minn. Statutes §145.64 and are subject to the limitations described at Minn. Statutes §145.65

11. Schwartz GF, Veronesi U, Clough KB, Dixon JM, Fentiman IS, Heywang-Kobrunner SH, et al. Consensus conference on breast conservation. *J Am Coll Surg* 2006;203(2):198-207.
12. Dunne C, Burke JP, Morrow M, Kell MR. Effect of margin status on local recurrence after breast conservation and radiation therapy for ductal carcinoma in situ. *J Clin Oncol* 2009;27(10):1615-20.
13. McCahill LE, Privette A, James T, Sheehey-Jones J, Ratliff J, Majercik D, et al. Quality measures for breast cancer surgery, initial validation of feasibility and assessment of variation among surgeons. *Arch Surg* 2009;144(5):455-62.
14. Kaufman CS, Shockney L, Rabinowitz B, Coleman C, Beard C, Landercasper J, et al. National Quality Measures for Breast Centers (NQMBC): A robust quality tool. *Ann Surg Oncol* 2010;17:377-85.
15. Rausei S, Rovera F, Gianlorenzo D, Tornese D, Fachinetti A, Boni L, et al. Predictors of loco-regional recurrence and cancer-related death after breast cancer surgery. *Breast J* 2010;16(suppl 1):S29-33.
16. Kouzminova NB, Aggarwal S, Aggarwal A, Allo MD, Lin AY. Impact of initial surgical margins and residual cancer upon re-excision on outcome of patients with localized breast cancer. *Am J Surg* 2009;198:771-80.
17. Allegra CJ, Aberle DJ, Ganschow P, Hahn SM, Lee CN, Millon-Underwood, S, et al. National Institutes of Health State-of-the-Science Conference Statement: Diagnosis and management of ductal carcinoma in situ September 22-24, 2009. *J Natl Cancer Inst* 2010;102(3):161-9.
18. Dick AW, Sobrero MS, Ahrendt GM, Hayman JA, Gold HT, Schiffhauer L, et al. Comparative effectiveness of ductal carcinoma in situ management and the roles of margins and surgeons. *J Natl Cancer Inst* 2011;103(2):92-104.
19. Anderson SJ, Wapnir I, Dignam JJ, Fisher B, Mamounas EP, Jeong JH, et al. Prognosis after ipsilateral breast tumor recurrence and locoregional recurrences in patients treated by breast-conserving therapy in five national surgical adjuvant breast and bowel project protocols of node-negative breast cancer. *J Clin Oncol* 2009; 27(15):2466-73.
20. Romond EH, Perez EA, Bryant J, Suman VJ, Geyer CE Jr, Davidson NE. Trastuzumab plus adjuvant chemotherapy for operable HER2-positive breast cancer. *N Engl J Med* 2005;353(16):1673-84.
21. Wiechmann L, Sampson M, Stempel M, Jacks LM, Patil SM, King T, Morrow M. Presenting features of breast cancer differ by molecular subtype. *Ann Surg Oncol* 2009;16:2705-10.
22. Wright MJ, Park J, Fey JV, Park A, O'Neill A, Tan LK, et al. Perpendicular inked versus tangential shaved margins in breast-conserving surgery: does the method matter? *J Am Coll Surg* 2007;204:541-9.
23. Clarke M, Collins R, Darby S, Davies C, Elphinstone P, Evans E, et al.; Early Breast Cancer Trialists' Collaborative Group (EBCTCG). Effects of radiotherapy and of differences in the extent of surgery for early breast cancer on local recurrence and 15-year survival: an overview of the randomized trials. *Lancet* 2005;366:2087-106.
24. Fisher B, Dignam J, Wolmark N, et al. Tamoxifen in treatment of intraductal breast cancer: National Surgical Adjuvant Breast and Bowel Project B-24 randomised controlled trial. *Lancet* 1999;353:1993-2000.

Guidelines are not meant to replace clinical judgment or professional standards of care. Clinical judgment must take into consideration all the facts in each individual and particular case, including individual patient circumstances and patient preferences. They serve to inform clinical judgment, not act as a substitute for it. These guidelines were developed by a Review Organization. These guidelines may be disclosed only for the purposes of the Review Organization according to Minn. Statutes §145.64 and are subject to the limitations described at Minn. Statutes §145.65

25. Silverstein MJ, Lagios MD, Groshen S, Waisman JR, Lewinsky BS, Martino S, et al. The influence of margin width on local control of ductal carcinoma in situ of the breast. *N Engl J Med* 1999;340:1455–61.
26. Wong JS, Kaelin CM, Troyan SL, Gadd MA, Gelman R, Lester SC, et al. Prospective study of wide excision alone for ductal carcinoma in situ of the breast. *J Clin Oncol* 2006;24:1031–6.
27. Horiguchi J, Lino U, Takei J, et al. Surgical margin and breast recurrence after breast-conserving therapy. *Oncol Reports* 1999;6:135–8.
28. Vicini FA, Kestin LL, Goldstein NS, et al. Relationship between excision volume, margin status, and tumor size with the development of local recurrence in patients with ductal carcinoma in situ treated with breast-conserving therapy. *J Surg Oncol* 2001;76:245–54.
29. Fisher ER, Costantino J, Fisher B, et al. Pathologic findings from the National Surgical Adjuvant Breast Project (NSABP) Protocol B-17. *Cancer* 1995;75:1310–9.
30. Holland PA, Gandhi A, Knox WF, et al. The importance of complete excision in the prevention of local recurrence of ductal carcinoma in situ. *Br J Cancer* 1998;77:110–4.
31. Cheng L, Al-Kaisi NK, Gordon NG, et al. Relationship between the size and margin status of ductal carcinoma in situ of the breast and residual disease. *J Natl Canc Inst* 1997;89:1356–60.
32. Fowble B, Hanlon MS, Fein DA, et al. Results of conservative surgery and radiation for mammographically detected ductal carcinoma in situ. *Int J Radiat Oncol Biol Phys* 1997;38:949–57.
33. Weng EY, Juillard GJF, Parker RG, et al. Outcomes and factors impacting local recurrence of ductal carcinoma in situ. *Cancer* 2000;88:1643–9.
34. Solin LJ, Fourquet A, Vicini FA, et al. Mammographically detected ductal carcinoma in situ of the breast treated with breast-conserving surgery and definitive breast irradiation: long-term outcome and prognostic significance of patient age and margin status. *Int J Radiat Oncol Biol Phys* 2001;50:991–1002.
35. Tartter PI, Kaplan J, Bleiweiss I, et al. Lumpectomy margins, reexcision, and local recurrence of breast cancer. *Am J Surg* 2000;179:81–5.
36. Hwang H, Sullivan ME, Susnik B. Lobular neoplasia. *Diagn Histopathol* (in press).
37. Sullivan ME, Khan SA, Sullu Y, Schiller C, Susnik B. Lobular carcinoma in situ variants in breast cores. *Arch Pathol Lab Med* 2010;134(7):1024-8.
38. Arora S, Menes TS, Moug C, Nagi C, Bleiweiss I, Jaffer S. Atypical ductal hyperplasia at margin of breast biopsy--is re-excision indicated? *Ann Surg Oncol* 2007;15(3):843–7.

Alternate Search Terms: N/A

Related Guidelines/Documents

Name	Content ID	Business Unit where Originated
Invasive Carcinoma: Management of Surgical Margins and Recommendations for Margin Re-excisions in Patients Having Breast Conserving Therapy	SYS-PC-OCSL-CG-004	System-wide

Guidelines are not meant to replace clinical judgment or professional standards of care. Clinical judgment must take into consideration all the facts in each individual and particular case, including individual patient circumstances and patient preferences. They serve to inform clinical judgment, not act as a substitute for it. These guidelines were developed by a Review Organization. These guidelines may be disclosed only for the purposes of the Review Organization according to Minn. Statutes §145.64 and are subject to the limitations described at Minn. Statutes §145.65